

# COMBINED PERICARDIECTOMY AND BEATING HEART CORONARY ARTERY BYPASS GRAFTING

Nádia Junqueira<sup>1#\*</sup>, Ricardo Ferreira<sup>1#</sup>, Ricardo Bernardo<sup>2</sup>, Ângelo Nobre<sup>1</sup>

<sup>1</sup>Cardiothoracic Surgery Department, Santa Maria Hospital, Lisbon, Portugal

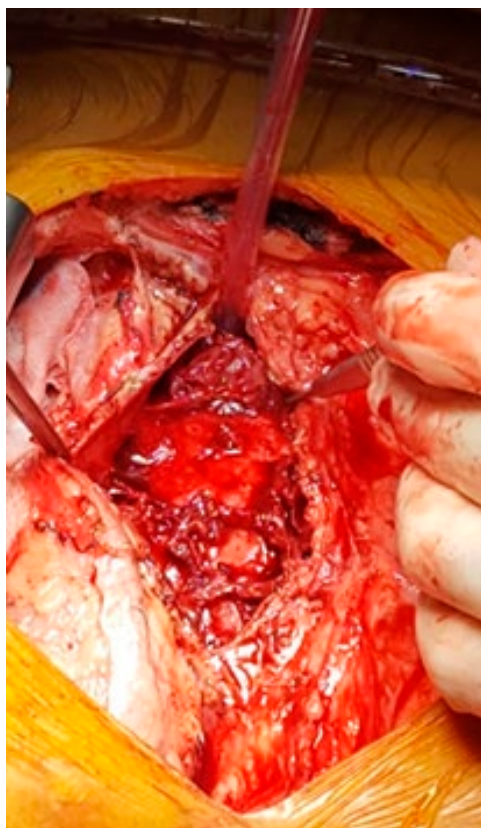<sup>2</sup>Anesthesiology Department, Santa Maria Hospital, Lisbon, Portugal

<sup>#</sup>Estes dois autores contribuíram equitativamente para o trabalho

\*Contacto Autor: nadia\_junqueira@hotmail.com

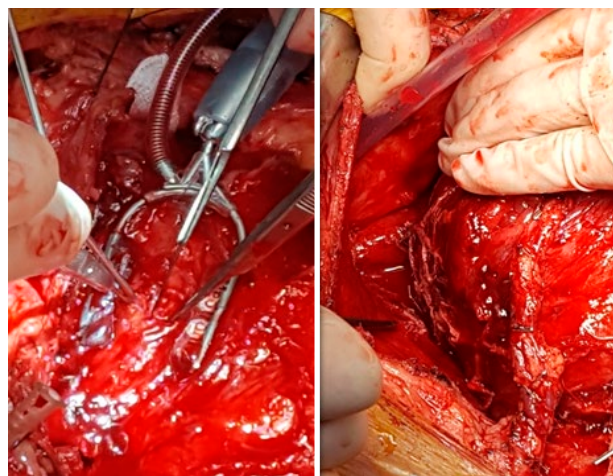
50-years-old male with three vessels coronary lesions. Intraoperatively thickened constrictive pericardium with multi-loculated hematic effusion. Ante-phrenic pericardiectomy was performed and the heart released

posteriorly, allowing mobilization. Off-pump LITA to LAD and SVG to PD anastomosis were performed. Post-operative uneventful. Histology confirmed chronic, idiopathic inflammation. A rare and challenging surgical procedure.



**Figure 1**

*Thickened constrictive pericardium with multi-loculated hematic pericardial effusion.*



**Figure 2**

*LITA to LAD anastomosis.*