

AORTIC ANASTOMOTIC ANEURYSM AFTER INFRA-RENAL GRAFTING

Mário Moreira¹, Luís Antunes¹, Joana Moreira¹, Gabriel Anacleto¹

¹Angiology and Vascular Surgery Department, Centro Hospitalar e Universitário de Coimbra, Coimbra, Portugal

*Contacto Autor: mariodpmoreira@gmail.com

An 87 year-old male presented with a 71mm proximal anastomotic aneurysm causing left renal artery displacement (Figures 1 and 2), 19 years after infra-renal aorto-aortic grafting for an infra-renal abdominal aortic aneurysm. Dilatation of visceral aorta was also observed. Management would be challenging but patient denied further intervention.

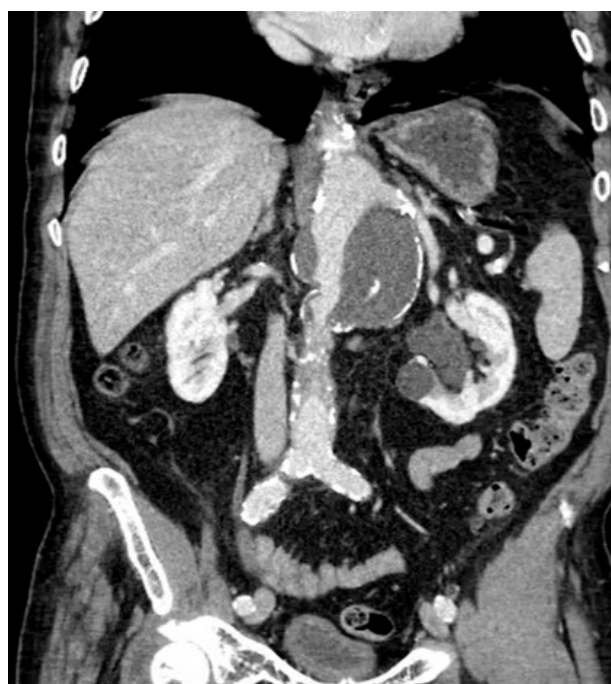

Figure 1

Aortic anastomotic aneurysm.

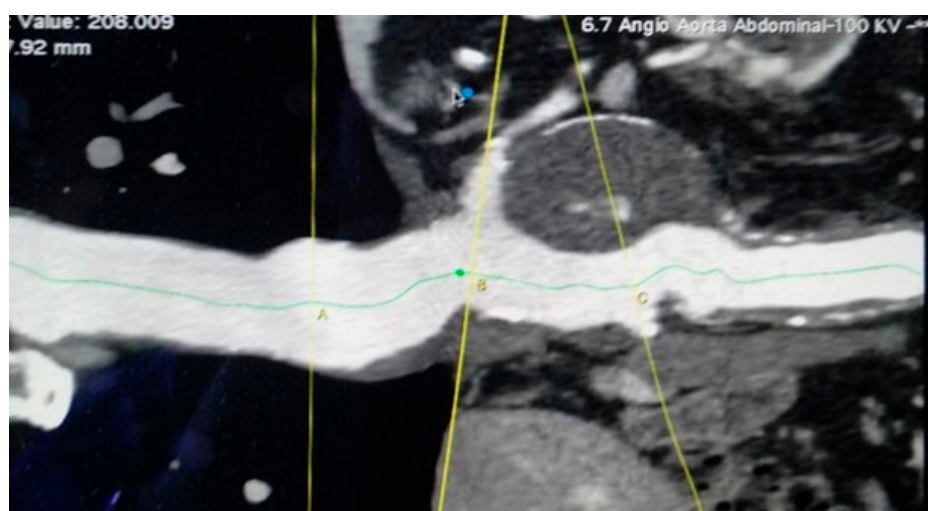


Figure 2

Left renal artery displacement. B line – left renal artery ostium, C line – right renal artery ostium.