

GIANT THORACIC MASS – THE STORY OF A SOLITARY FIBROUS TUMOUR

Susana Lareiro¹, Filipe Leite^{*2}, Gonçalo Paupério²

¹ Serviço de Cirurgia Cardiorácica, Centro Hospitalar de Vila Nova de Gaia
² Serviço de Cirurgia Cardiorácica, Instituto Português de Oncologia do Porto

* Corresponding author: filipe.miguel.leite@outlook.com

Abstract

The tumours of the pleura are a vast and diverse field. One of the lesser known and less common tumour is the solitary fibrous tumour of the pleura, representing about 5% of these types of tumours. The authors present the case of a woman admitted to the emergency department with symptoms of dizziness and vomits. Imaging studies showed a giant thoracic mass on the left hemithorax, with a biopsy indicating a solitary fibrous tumour. The patient was referred for surgery, which was performed via thoracotomy. In the postoperative period she developed an acute pulmonary oedema secondary to lung reexpansion and fluid overload, with a good response to fluid restriction and intravenous diuretics.

INTRODUCTION

Tumours of the pleura are a vast and diverse field. One of the lesser known and less common tumour is the solitary fibrous tumour of the pleura, representing about 5% of these types of tumours. Solitary fibrous tumours can arise from visceral organs or mesothelial tissues, and as such have been described in many other locations.

The tumour often presents no symptoms and is usually randomly discovered during a routine chest x-ray.

CASE REPORT

A 71 year old woman was admitted in the emergency department due to sudden dizziness and vomits.

She also mentioned dyspnoea which had gotten worse in the past few months.

Upon examination she had absent pulmonary sounds on the left side and an O₂ saturation of 92%, as well as a type 2 respiratory insufficiency. Chest x-ray and CT scan showed a mass occupying the left hemithorax with 22x11 cm, collapsing the lung and apparently invading the mediastinum. (figure 1 and 2) Upon further analysis of past chest x-rays, a smaller mass was already visible going back 2 years.

She was admitted into the infirmary for further study and medical treatment. A biopsy of the mass showed a fibrous solitary tumour of the pleura. Upon clinical improvement with non-invasive ventilation, the patient was discharged and referred to the author's hos-

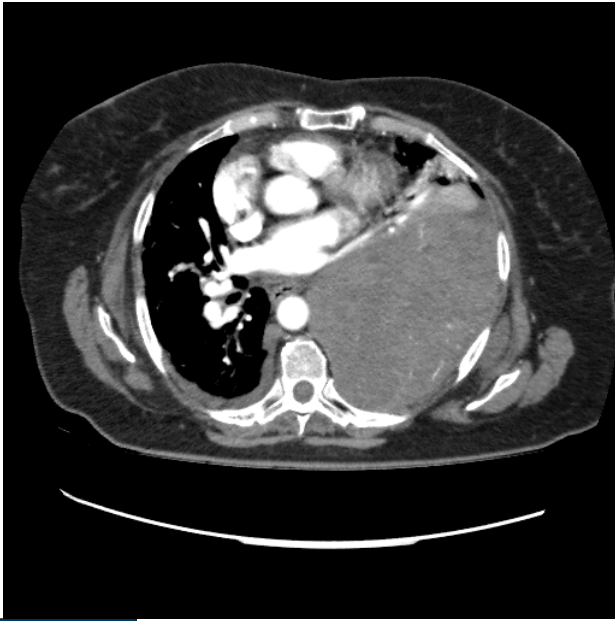

Figure 1

Axial view showing the mass occupying the left hemithorax with 22x11 cm, collapsing the lung and apparently invading the mediastinum.

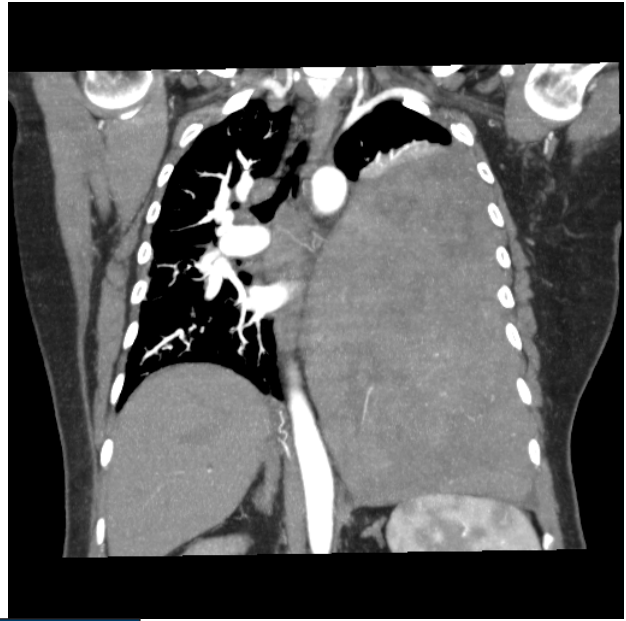


Figure 2

Coronal view of the mass shown compressing and distorting the mediastinum.

pital cardiothoracic surgery department.

Preoperative study showed a FEV1 of 38%, without DLCO due to the patient's inability to perform the manoeuvre.

Still, as the removal of the mass would only improve lung capacity, the team opted to go ahead.

A left thoracotomy through the 5th intercostal space was performed and dissection from the chest wall, mediastinum and lung was performed, as the tumour did not invade any structure. (figure 3) Two vascular pedicles were identified and ligated, one originating from the left lower lobe and the other from the posterior portion of the seventh intercostal artery, and the mass was safely removed (figure 4).

The postoperative period was complicated by an acute pulmonary oedema secondary to acute lung injury after reexpansion of the lung and fluid overload. The patient was put on furosemide and methylprednisolone and made an uneventful recovery and was discharged on the eleventh postoperative day.

DISCUSSION

Representing about 5% of the tumours of the pleura⁵, with only between 800 and 960 cases reported^{1,2}. Solitary fibrous tumours often presents no symptoms, but can present with paraneoplastic syndromes such as Doege-Potter Syndrome^{3,4}, and is usually randomly discovered during a routine imaging exam, as was the case. The patient did mention a progressively worsening dys-

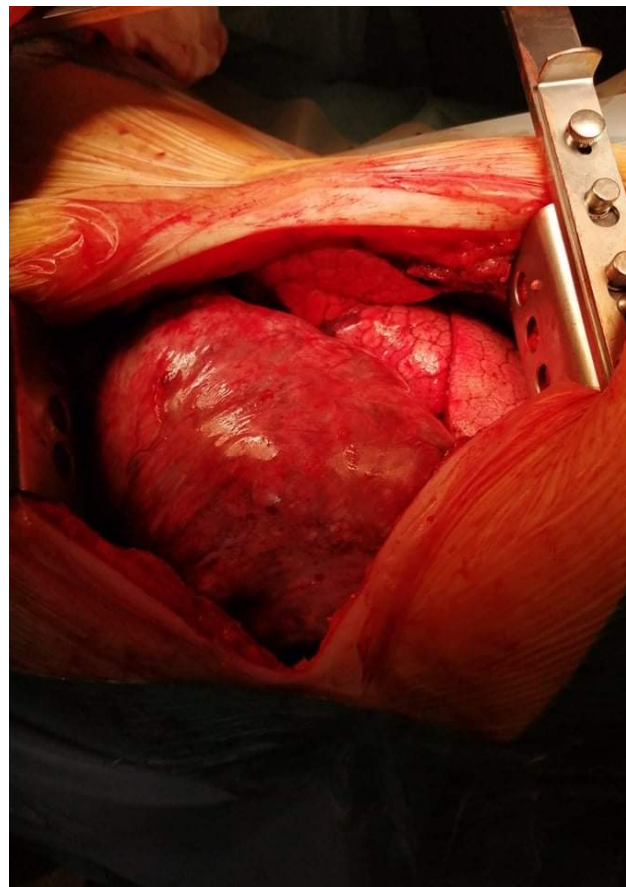


Figure 3

Intraoperative photograph of the thoracic mass partially collapsing the left lung

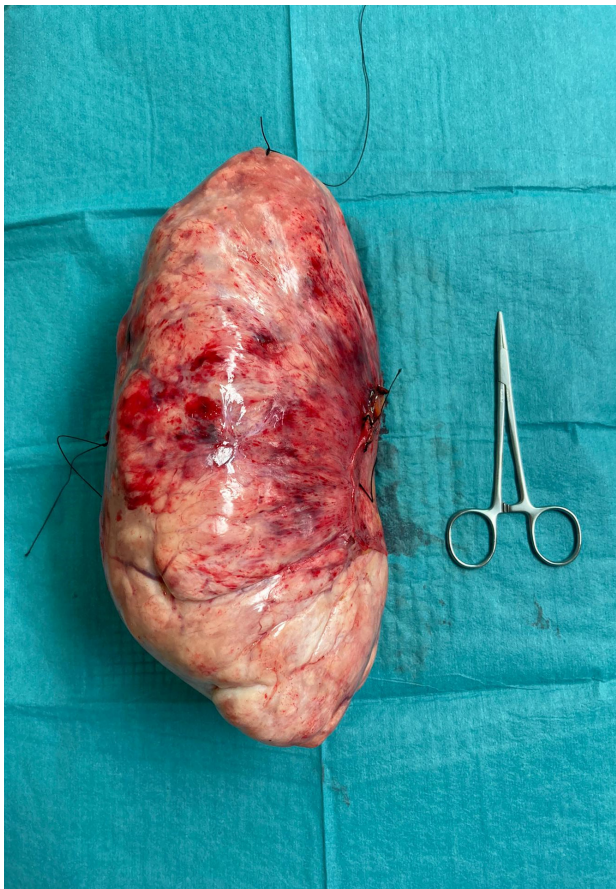

Figure 4

Mass compared with an 125 mm Halsted Mosquito Forceps.

pnoea, which was never explored, and it was non-related symptoms that lead to the going to the ER.

A point could be raised as to the FEV1 of 38%, but after discussion with the anaesthesiologist and as the left lung was practically non-functioning, it was decided that the risk was manageable, but single lung ventilation was not possible, and that as soon as the mass was removed ventilation would improve gradually, as was proven.

Several case reports indicate the possibility of a

minimally invasive approach, but limit this to small, well defined masses⁵. In the presented case, the mass was far too large for such a technique and a thoracotomy was warranted.

In the postoperative period the patient developed an acute pulmonary oedema secondary to acute lung injury after reexpansion of the lung and fluid overload. This entity is described for sudden reexpansion following pneumothorax drainage, but to the best of our knowledge not following removal of a large pleural mass.

In conclusion, solitary fibrous tumours are a rare entity, often times presenting as large thoracic masses, but are usually resectable, require a multidisciplinary approach and careful optimization pre and postoperatively.

REFERENCES

1. Cardillo G, Lococo F, Carleo F, et al. Solitary fibrous tumours of the pleura. *Curr Opin Pulm Med* 2012; 18: 339–346.
2. dePerrot M, Fischer S, Brundler MA, et al. Solitary fibrous tumours of the pleura. *Ann Thorac Surg* 2002; 74: 285–293.
3. Junqueira N, Caldeira J, Ferreira R, Costa F, Silva J, Monteiro T, Nobre Â. Giant Pleural Tumor And Severe Hypoglycemia: Doegge-Potter Syndrome In A Previously Healthy Female. *Rev Port Cir CardioracVasc*. 2020 Jul-Sep;27(3):223-226. PMID: 33068515.
4. You, Y.-H., Liu, R.-T., & Zhang, Y. (2018). A large solitary fibrous tumour of the pleura: a case report and review of the literature. *Journal of International Medical Research*, 46(4), 1672–1677.
5. Hohenforst-Schmidt, W., Grapatsas, K., Dahm, M., Zarogoulidis, P., Leivaditis, V., Kotoulas, C., ... Kosan, B. (2017). Solitary fibrous tumour: A center's experience and an overview of the symptomatology, the diagnostic and therapeutic procedures of this rare tumour. *Respiratory Medicine Case Reports*, 21, 99–104. doi:10.1016/j.rmcr.2017.04.007