

CORONARY ARTERIES - WHEN CALCIFICATION POPS UP

Joana Raquel Monteiro¹, Sónia Salgueiro¹, Fernanda Pinhal¹

¹ 1Serviço Medicina 2, Centro Hospitalar de Leiria, Portugal

* Corresponding author: joana.r.monteiro@chleiria.min-saude.pt

An 84-year-old woman, with background history of atrial fibrillation, cerebral vascular disease, ischemic heart failure by coronary disease with several stent im-

plantation, presented in the emergency room with syncope. The chest radiograph evidenced the coronary trajectory by their calcification.

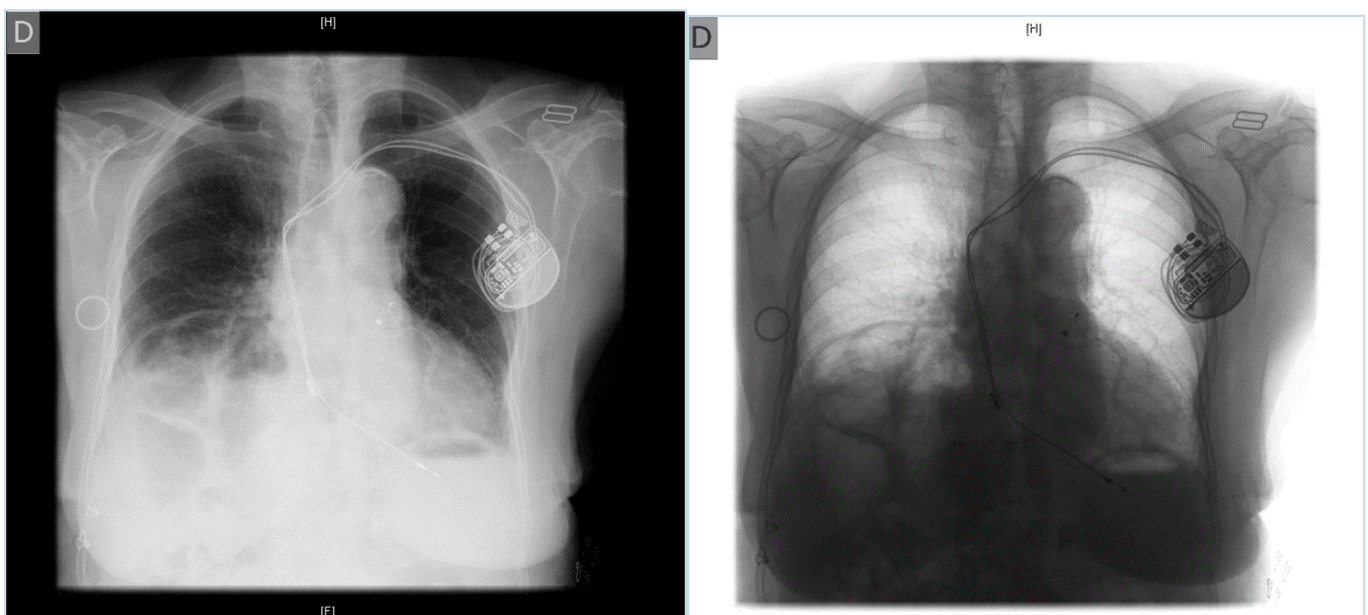


Figure 1

Coronary calcification.