

# IMPENDING VENTRICULAR SEPTAL DEFECT: IS IT REASONABLE TO BE CONSERVATIVE?

Mariana Santos Castro<sup>1</sup>, João Abecasis<sup>1,2</sup>, Ana Braga<sup>3</sup>, José Pedro Neves<sup>3</sup>

<sup>1</sup>Serviço de Cardiologia, Hospital de Santa Cruz, Carnaxide, Portugal

<sup>2</sup>Faculdade de Ciências Médicas, Universidade Nova de Lisboa

<sup>3</sup>Serviço de Cirurgia-Cardíaca, Hospital de Santa Cruz, Carnaxide, Portugal

\*Contacto Autor: marianacpsc@gmail.com

A 72 year-old men admitted for a two week old myocardial infarction had a septal intra-myocardial cavity at first echocardiographic evaluation (A,B). Cardiac magnetic resonance showed extensive no-reflow on the septum

(C). Owing to clinical stability, a conservative strategy was decided. Without a complete VSD (D), fibrosis filled the gap in two weeks (E), followed by a septal remodelling scar (F).

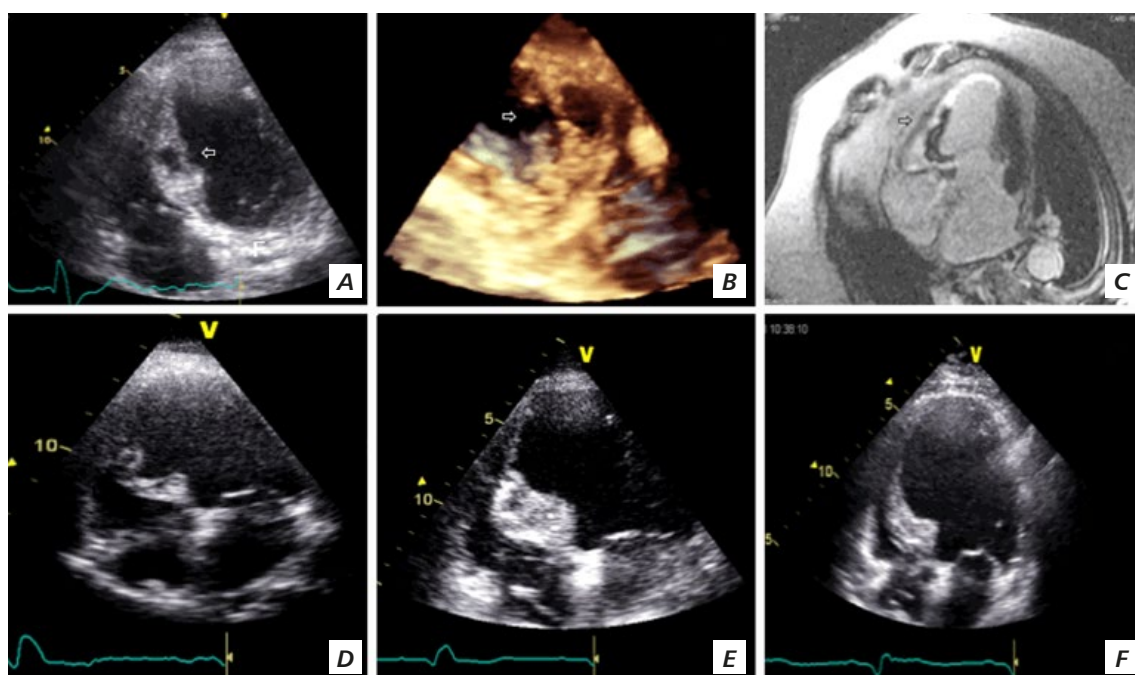


Figure 1